

RESEARCH PAPER

Ruptured abdominal aortic aneurysm diagnosed through non-contrast MRI

Priyank S Chatra

Address for Correspondence:

Priyank S Chatra

Department of Radiology, Badr Al Samaa Hospitals,
Muscat, Oman

Email: khiladi001980@yahoo.co.in

<http://dx.doi.org/10.5339/qmj.2013.16>

Submitted: 5 September 2013

Accepted: 1 January 2014

© 2014 Chatra, licensee Bloomsbury Qatar Foundation Journals. This is an open access article distributed under the terms of the Creative Commons Attribution license CC BY 3.0, which permits unrestricted use, distribution and reproduction in any medium, provided the original work is properly cited.

Cite this article as: Chatra PS. Ruptured abdominal aortic aneurysm diagnosed through non-contrast MRI, Qatar Medical Journal 2013;16 <http://dx.doi.org/10.5339/qmj.2013.16>

 **QSCIENCE.com**
Member of Qatar Foundation

ABSTRACT

Rupture of an aneurysm is a rare complication although it is considered a common cause of death. Some of these patients present with the classic triad of symptoms such as abdominal pain, pulsatile abdominal mass and shock. Most symptoms are misleading and will only present as vague abdominal pain. Here we describe one such patient with an unusual presentation of a misleading abdominal mass which was eventually diagnosed as a ruptured abdominal aortic aneurysm after an emergency MRI.

Keywords: aneurysm, abdominal aorta, rupture

INTRODUCTION

Aneurysm is defined as an abnormal dilatation or bulge in the wall of a vessel. Aneurysms are classified as fusiform or saccular type based on the morphology. An aneurysm that extends from the thoracic aorta into the abdominal aorta is called thoraco-abdominal aneurysm.⁽¹⁾ Rupture is a dreaded complication of abdominal aortic aneurysms with a mortality rate of 90%. 40% of the mortality is seen before admission to hospital and another 40-50% in the perioperative period or 30 days post-surgery.⁽²⁾

CASE REPORT

A 70-year-old female Filipino patient arrived at the emergency department with severe abdominal pain. On general physical examination, the patient was obese and was restless and irritated. Her abdomen was tender on palpation and a vague abdominal mass was felt. Tenderness could be elicited from all quadrants of the abdomen. On clinical examination her pulse rate was 80/min and her blood pressure was 130/80 mm Hg.

A previous blood examination report read: blood hemoglobin: 9.6 g/dl; total cell count 13.4k/ μ L with 70% neutrophils, platelet count 150k/ μ L; blood uric acid 4.8 mg/dl and serum creatinine 2.6 mg/dl.

Repeat blood examination was ordered. The clinician suspected an underlying cardiac condition and a troponin T test was ordered. Liver and renal function tests were also done in suspicion of renal failure.

In view of the presence of the vague abdominal mass, the patient was referred for abdominal ultrasonography (USG) pending the blood investigations. Abdominal USG revealed the presence of a collection in the midline abdomen and also fluid collection in bilateral paracolic gutters.

Following this, results of the blood investigations came back and were as follows: hemoglobin: 7.6 g/dl; total cell count 14.5k/ μ L with 60% neutrophils, platelet count 150k/ μ L; blood uric acid 5.3 mg/dl and serum creatinine was 1.5 mg/dl. Trop T was negative. Both renal and liver function tests were within normal limits.

The clinician observed that there was a significant drop in the hemoglobin count compared to the previous count. Meanwhile, the patient's condition deteriorated with a fall in pulse and a BP of 110/80 mm Hg. The clinician came to the conclusion that was a loss of blood somewhere in the abdomen which was leading to the patient's drop in hemoglobin, as well as her general physical state. The patient was put on ionotrops and her BP was maintained at 120/80 mm Hg.

Clinical diagnosis of a vague abdominal mass with possible intra-abdominal bleeding was made and then the patient was sent for MRI for further evaluation and to look for the bleeding abdominal mass. CT of the abdomen was not in the line of investigation as the clinician was not considering a ruptured abdominal aortic aneurysm a cause of the symptoms.

On MRI, to complete surprise, an enlarged and tortuous abdominal aortic and aneurysm that was bleeding through a rupture was found. Abdominal aortic aneurysm was not picked up on USG let alone a ruptured abdominal aortic aneurysm.

There was proximal extension of the aneurysm into the thoracic aorta. The aneurysm was fusiform type with a distal extension into both the iliac arteries. The right iliac artery was also showing another saccular dilatation (Figure 1). The true lumen was significantly compressed in both the iliac arteries. In addition, there was a focal defect seen in the right iliac artery

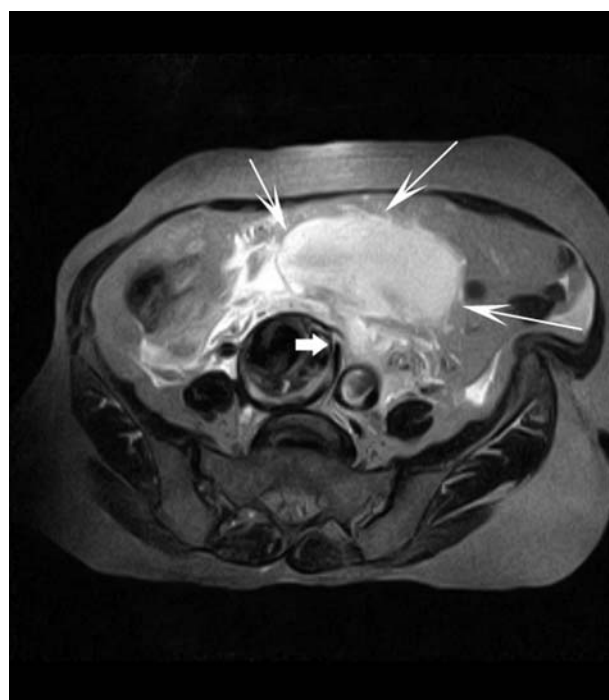


Figure 1. T2W axial image showing hyperintense (arrows) retroperitoneal hematoma. Saccular aneurysm is also seen in the right iliac artery with a focal defect in the intima (thick arrow) signifying site of rupture.

aneurysm signifying rupture (Figure 2). A large hyperacute hematoma was seen in the retroperitoneum. There was extension of this hematoma into bilateral paracolic gutters and also into the pelvis.

A radiological diagnosis of ruptured abdominal aorta aneurysm was made and the patient was rapidly returned to emergency for further management.

Following MRI, all the findings made sense. Hemoglobin was reduced due to blood loss and only vague complaints were given as the patient was in shock. Meanwhile, the patient's condition deteriorated further with a significant drop in pulse and blood pressure. One pint of blood was transfused in order to compensate for the lost blood in the ruptured aneurysm. The vascular surgeon was called in with a view to open repair of the ruptured aneurysm. The patient was then transferred to the operating theatre for emergency surgery, upon this, the patient died. An attempt to revive the patient was made, however, was unsuccessful.

DISCUSSION

Abdominal aortic aneurysms (AAA) by definition are more than 3 cm in diameter. AAA was thought to be an advancement of atherosclerosis, but now is

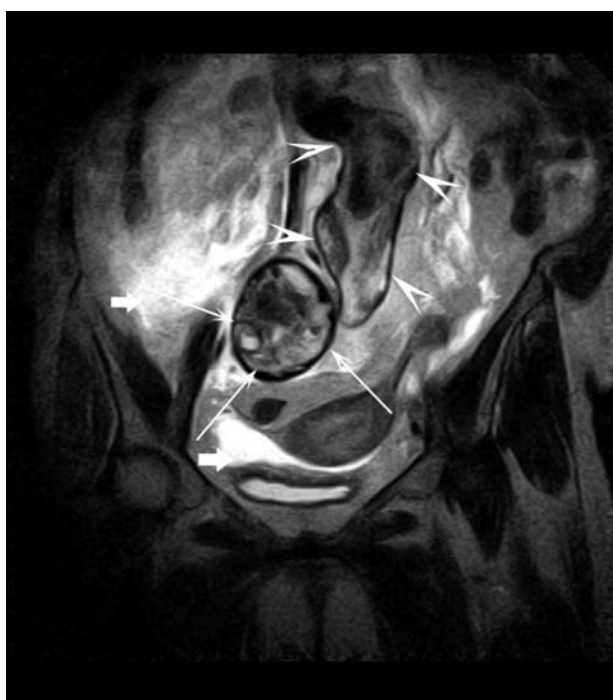

Figure 2. T2W coronal image showing dilated tortuous abdominal aortic aneurysm (arrowheads) with a focal saccular aneurysm in the right iliac artery (arrows) and intraperitoneal extension of the hematoma (thick arrows) into the paracolic gutters and into the pelvis.

described as focal representation of a systemic vascular disease. It was also thought to be a complication of atherosclerosis, and rupture was thought to be a simple mechanical process where the wall of the aneurysm gives way due to increased hemodynamic stress.⁽³⁾ Pathophysiology of AAA is now presumed to be secondary to inflammation and excessive extracellular matrix breakdown leading to aortic expansion and formation of aneurysm.

Formation of AAA is attributed to the presence of excessive elastolysis which degrades the wall of the aorta. The degraded wall is then acted upon by inflammatory cytokines and proteases which lead to further expansion resulting in focal rupture.⁽⁴⁾ Predisposing factors for abdominal aortic aneurysm are males, positive family history, concurrent coronary artery disease, peripheral vascular disease and smoking. The majority of abdominal aortic aneurysms are seen to arise below the origin of renal arteries and may or may not extend into the iliac arteries.⁽⁵⁾

The predisposing factor for rupture is a large cross-sectional diameter of the aneurysm. Aneurysms which are more than 7 cm in diameter have a 32.5% increased chance of rupture.⁽⁶⁾ Other high risk factors for rupture are, expansion rate >0.6 cm/year,

females, history of smoking and COPD, poorly controlled hypertension, family history of AAA and high wall stress ($>45\text{N/cm}^2$).⁽⁷⁾ Common sites of rupture include intraperitoneal rupture and retroperitoneal rupture. Rare sites include aorta caval fistula and aortoduodenal fistula.⁽²⁾

Classic clinical presentation of these patients is with a triad of symptoms namely, abdomen pain or backache, hypotension and a pulsatile abdominal mass. However, this presentation is seen only in 25 – 50% of patients. The remainder may present with vague abdominal pain or shock.⁽⁵⁾ Rare presentations of ruptured AAA include inguinal hernia,⁽⁸⁾ buttock pain,⁽⁹⁾ appendicitis⁽¹⁰⁾ and testicular pain.⁽¹¹⁾ Almost half of all ruptured AAA are likely to be misdiagnosed. The most common misdiagnosis includes renal colic, diverticulitis and gastrointestinal hemorrhage. The most common initial physical findings in misdiagnosed patients includes abdominal pain, shock and back pain. Our patient was also initially misdiagnosed with gastrointestinal bleeding as she presented with abdominal pain.

Imaging diagnosis relies on the demonstration of dilatation of the abdominal aorta and leakage of blood from the rupture. CT abdomen is the imaging modality of choice for a suspected ruptured abdominal aortic aneurysm. CT abdomen was not done in our patient because the initial clinical diagnosis was that of a bleeding abdominal mass. Nevertheless, CT findings of ruptured aortic aneurysms include focal discontinuity in the intimal calcification with or without extravasation of contrast from the lumen. Retroperitoneal hematoma appears as focal area of hyperdensity in the retroperitoneal space surrounding the aorta. Intraperitoneal hematoma appears as hyperdense fluid collection in the respective peritoneal compartment.

CT is also useful in the follow-up of known cases of abdominal aortic aneurysms where signs of impending rupture can be looked for. CT can also be used for pre-operative assessment for endovascular aneurysm repair (EVAR).⁽¹¹⁾ USG abdomen is the first and foremost imaging modality feasible in an emergency setting. USG can show the presence of hyperechoic collection in the retroperitoneal space and also in the intraperitoneal spaces. USG also shows the proximal and distal extent of the aneurysm which helps in planning of further imaging.⁽¹²⁾

MRI is not the imaging modality in acute settings as it is primarily time consuming and may waste valuable time required for emergency surgery. MRI findings

of ruptured AAA include loss of continuity of full thickness of enlarged tortuous aorta at the site of rupture. Secondary signs of rupture include presence of intraperitoneal and retroperitoneal hematoma. Other findings include loss of continuity of intimal calcification appreciated on GRE images.⁽¹³⁾ The retroperitoneal hematoma is seen as a collection surrounding the retroperitoneal organs. In a hyper-acute stage, the collection appears hypointense on T1, and hyperintense on T2 with shortening on GRE images. The intraperitoneal hematoma can be differentiated from retroperitoneal hematoma by the extension of the collection into the supra and infra mesocolic spaces and extension into the paracolic gutters.⁽¹⁴⁾

Perioperative mortality is increased in patients with increased age (> 80 yrs), in females, poor physical activity and also presence of comorbidities such as cardiac disease, poor renal and liver functions.⁽¹⁵⁾ Mortality rate was not found to be significantly different in misdiagnosed patients as compared to correctly diagnosed patients.⁽¹⁶⁾ Our patient was 70 years old which put her in a moderate risk category and although her serum creatinine level was normal at the time of rupture, an old report suggesting high creatinine level would probably suggest that she had abnormal renal function. Others factors such as poor physical activity, large amounts of blood loss and loss of time in correcting the misdiagnosis and use of MRI and lastly being female might have contributed to her fatality.

According to The Society for Vascular Surgery Practice Guidelines for surveillance of AAA, it is recommended that men greater than 65 years should undergo one-time ultrasound screening. Screening should start as early as 55 years for all men with family history of AAA. One-time USG screening is also recommended for women greater than 65 years and with a family history of AAA or who have smoked. Screening of AAA is not recommended for patients 65 years and over if aortic diameter is less than 2.6 cm. Surveillance imaging is recommended for patients with an aortic diameter from 3.5 to 4.4 cm at 12 month intervals. Six monthly surveillance imaging

is recommended for patients with an aortic diameter of 4.5 to 5.5 cm. Three yearly follow-up imaging is recommended for those patients with AAA of 3.0 to 3.4 cm and five yearly follow-up is recommended for patients with AAA of 2.6 to 2.9 cm.⁽¹⁷⁾

Current surgical practice insists all patients with AAA > 5.5 cm to have surgery if they are surgically fit and to follow-up with 6 monthly USG for all patients with AAA < 5.5 cm. The small aneurysms are then referred back to surgery if expansion rate exceeds > 1 cm/year or the diameter exceeds > 5.5 cm.⁽¹⁸⁾

Management of ruptured abdominal aortic aneurysms can be done either by open surgery or endovascular aneurysm repair. EVAR is increasingly preferred over open repair due to the lack of operative risk. However, EVAR is advocated for patients with impending rupture and who are hemodynamically stable. Open surgery is the treatment of choice in patients with ruptured aneurysms who are hemodynamically unstable and in the emergency setting.⁽¹⁹⁾ Multiple randomized control trials were conducted across the globe pitching EVAR vs. open repair.^(20,21,22) Most of the trials have come to a consistent conclusion that perioperative mortality and morbidity is significantly lower in EVAR as compared to open repair. However, rates of graft related complications and reintervention rates are higher in EVAR. Long term survival rates are similar in both groups. It is emphasized that careful selection of devices and patients are essential for a good long term outcome for EVAR.⁽²³⁾

CONCLUSION

Ruptured abdominal aortic aneurysms are a surgical emergency with very high mortality rates. Clinicians should be aware of unusual presentations that are associated with this condition. Early diagnosis and prompt treatment can be life saving for the patient. CT is the imaging modality of choice in suspected cases of ruptured abdominal aortic aneurysms. EVAR is the preferred treatment in hemodynamically stable patients with impending rupture. Open surgery is the treatment of choice in acute settings.

REFERENCES

1. Scot RA, Aston HA, Kay DN. Abdominal aorta aneurysm in 4,237 screened patients: prevalence, development and management over 6 years. *Br J Surg.* 1991;78:1122 – 1125.

2. Assar AN, Zarins CK. Ruptured abdominal aortic aneurysm: a surgical emergency with many clinical presentations. *Postgrad Med J*. 2009;85:268 – 273.
3. Choke E, Cockerill G, Wilson WRW, Sayed S, Dawson J, Loftus I, Thompson MM. A review of biological factors implicated in abdominal aortic aneurysm rupture. *Eur J Vasc Endovasc Surg*. 2005; 30(3):227 – 244.
4. Satta J, Haukipuro K, Kairaluoma MI, Juvonen T. Aminoterminal propeptide of type III procollagen in the follow-up of patients with abdominal aortic aneurysms. *J Vasc Surg*. 1997;25:909 – 915.
5. Durdu T, Yilmaz F, Sönmez BM, Ülgen S, Demir A, Yölmaz MS, Arslan ED, Hakbilir O. An unusual presentation of ruptured abdominal aorta aneurysm. *Am J Case Rep*. 2013;14:267 – 269.
6. Lederle FA, Johnson GR, Wilson SE, Ballard DJ, Jordan WD, Blebea J, Littooy FN, Freischlag JA, Bandyk D, Rapp JH, Salam AA. Rupture rate of large abdominal aortic aneurysms in patients refusing or unfit for elective repair. *JAMA*. 2002;287(22):2968 – 2972.
7. Brewster DC, Cronenwett JL, Hallett JW Jr, Johnston KW, Krupski WC, Matsumura JS. Guidelines for the treatment of abdominal aortic aneurysms. Report of a subcommittee of the Joint Council of the American Association for Vascular Surgery and Society for Vascular Surgery. *J Vasc Surg*. 2003 May;37(5):1106 – 1117.
8. Moissinac K, Boon Chong Se To, Liew NC, Yunus Gul. Abdominal aortic aneurysm rupture masquerading as strangulated inguinal hernia. *Am J Emerg Med*. 2001;19:604 – 605.
9. Mahmood F, Ahsan F, Hockey M. Ruptured abdominal aortic aneurysm presenting as buttock pain. *Emerg Med J*. 2005;22:453 – 454.
10. Garb M. Appendicitis: an unusual cause of infected abdominal aortic aneurysm. *Australas Radiol*. 1994;3:68 – 69.
11. Sufi P. A rare case of leaking abdominal aneurysm presenting as isolated right testicular pain. *Can J Emerg Med*. 2007;9:124 – 126.
12. Rakita D, Newatia A, Hines JJ, Siegel DN, Friedman B. Spectrum of CT findings in rupture & impending rupture of abdominal aortic aneurysms. *Radiographics*. 2007;27:497 – 507.
13. Takayama T, Yamanouchi D. Aneurysmal disease: the abdominal aorta. *Surg Clin North Am*. 2013; 93(4):877 – 891.
14. Kramer CM, Cerilli LA, Hagspiel K, Di Maria JM, Epstein FH, Kern JA. Magnetic resonance imaging identifies the fibrous cap in atherosclerotic abdominal aortic aneurysm. *Circulation*. 2004;109:1016 – 1021.
15. The UK Small Aneurysm Trial Participants. Mortality results for randomized controlled trial of early elective surgery or ultrasonographic surveillance for small abdominal aortic aneurysms. *Lancet*. 1998;353:1649 – 1655.
16. Marston WA, Ahlquist R, Johnson G Jr, Meyer AA. Misdiagnosis of ruptured abdominal aortic aneurysms. *J Vasc Surg*. 1992;16(1):17 – 22.
17. Chaikof EL, Brewster DC, Dalman RL, Makaroun MS, Illig KA, Sicad GA, Timaran CH, Upchurch GR Jr, Vieth FJ. SVS practice guidelines for the care of patients with an abdominal aortic aneurysm: executive summary. *J Vasc Surg*. 2009; 50(4):880 – 896.
18. McGlothin TM, Doyle BJ. New approaches to abdominal aortic rupture risk assessment: engineering insights with clinical gain. *Arterioscler Thromb Vasc Biol*. 2010;30:1687 – 1694.
19. Visser JJ, van Sambeek MR, Hamza TH, Hunink MG, Bosch JL. Ruptured abdominal aortic aneurysms: endovascular repair versus open surgery—systematic review. *Radiology*. 2007;245:122 – 129.
20. Greenhalgh RM, Brown LC, Powell JT, Thompson SG, Epstein D, Sculpher MJ. United Kingdom EVAR Trial Investigators. Endovascular versus open repair of abdominal aortic aneurysm. *N Engl J Med*. 2010;362:1863 – 1871.
21. De Bruin JL, Baas AF, Buth J, Prinssen M, Verhoeven EL, Cuypers PW, van Sambeek MR, Balm R, Grobbee DE, Blankensteijn JD, DREAM Study Group. Long-term outcome of open or endovascular repair of abdominal aortic aneurysm. *N Engl J Med*. 2010;362:1881 – 1889.
22. Lederle FA, Freischlag JA, Kyriakides TC, Padberg FT Jr, Matsumura JS, Kohler TR, Lin PH, Jean-Claude JM, Cikrit DF, Swanson KM, Peduzzi PN, Open Versus Endovascular Repair (OVER) Veterans Affairs Cooperative Study Group. Outcomes following endovascular vs open repair of abdominal aortic aneurysm: a randomized trial. *JAMA*. 2009;302:1535 – 1542.
23. Schanzer A, Messina L. Two Decades of Endovascular Abdominal Aortic Aneurysm Repair: Enormous Progress With Serious Lessons Learned. *J Am Heart Assoc*. 2012;1:e000075.